

# Spinal Cord and Spinal Nerves

## Chapter 12

### SPINAL CORD

1. The spinal cord conducts action potentials to and from the brain.
2. The spinal cord processes sensory input and produces output that results in a stereotypic response called a reflex.

### General Structure

FIGURE 12.1

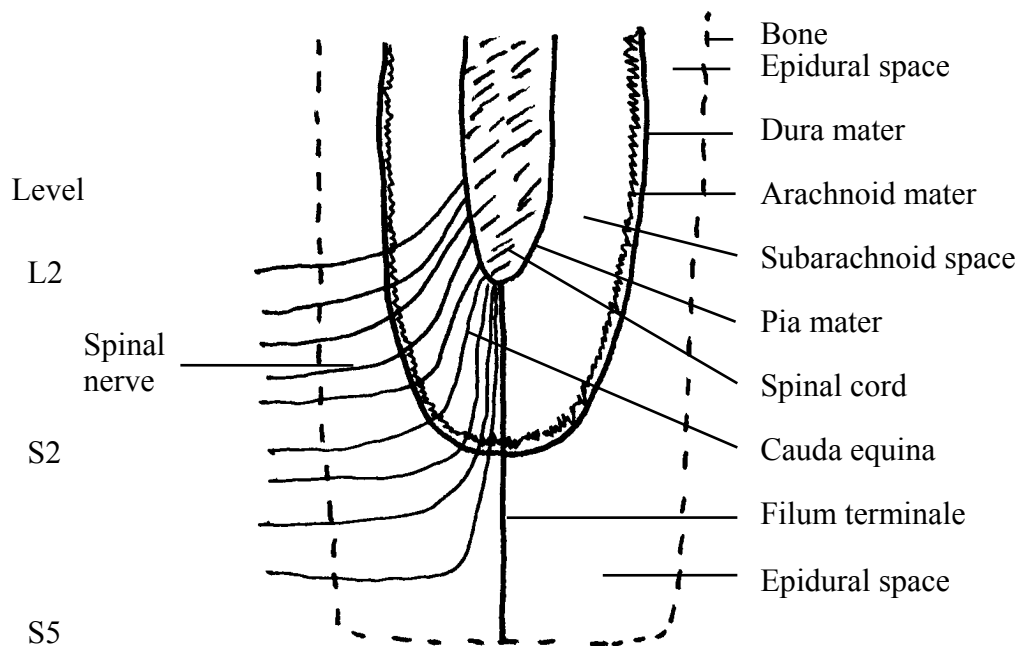
1. The **spinal cord** extends from the level of the foramen magnum to the level of the second lumbar vertebra. The spinal cord extends only to the level of the second lumbar vertebra because the vertebral column grows more during development than does the spinal cord.
2. There are 31 pairs of spinal nerves which leave the spinal cord and pass through the intervertebral foramina.
3. Some parts of the spinal cord are larger than other parts.
  - A. The **cervical enlargement** supplies the upper limbs.
  - B. The **lumbar enlargement** supplies the lower limbs.
4. Inferior to the lumbar enlargement the spinal cord tapers to form the **conus medullaris**.
5. Although the conus medullaris ends at the level of the second lumbar vertebrae, spinal nerves arising from the conus medullaris extend through the vertebral canal and exit the vertebral column at lower levels. This collection of spinal nerves within the vertebral canal is called the **cauda equina** (horse's tail).

### Meninges of the Spinal Cord

FIGURE 12.2

1. The spinal cord and brain are surrounded by membranes called the **meninges** (L. membrane; meninx = singular). They provide protection and help to hold the spinal cord and brain in place.
2. **Dura mater** (L. hard mother).
  - A. The dura mater is the most superficial meninx surrounding the spinal cord. It is also the strongest, thickest meninx.
  - B. The **epidural space** is the space between the wall of the vertebral canal and the dura mater of the spinal cord. It is filled with fat, blood vessels, and the spinal nerves as they leave the spinal cord.

- C. **Epidural anesthesia** can be accomplished by inserting a needle into the epidural space through the sacral hiatus (the inferior opening of the sacral canal) or between lumbar vertebrae and injecting a drug that prevents action potential propagation in the spinal nerves.
3. **Arachnoid mater** (L. spider-like).
- The arachnoid mater is a delicate, cobwebby membrane beneath the dura mater.
  - The arachnoid mater is separated from the dura mater by the **subdural space**, which is filled with a small amount of serous fluid.
4. **Pia mater** (L. tender mother).
- The pia mater, the innermost meninx, is a delicate membrane with many blood vessels. It adheres to the surface of the spinal cord.
  - The **subarachnoid space** is between the arachnoid mater and pia mater. It is a relatively large space filled with **cerebrospinal fluid** (described in chapter 13) and blood vessels.
5. The subarachnoid space is the site of clinical tests. The spinal cord extends to about level L2 of the vertebral column. The meninges extend to level S2. A needle can be inserted into the subarachnoid space between vertebrae L3 and L4.
- A **spinal tap** is the removal of cerebrospinal fluid to check for infectious agents. The procedure can also be used to detect bleeding and to measure the pressure of cerebrospinal fluid.
  - A **myelogram** is a radiograph (x-ray photograph) made after the injection of a dye into the subarachnoid space. It is used to check for damage to an intervertebral disk or the spinal cord.
- C. **Spinal anesthesia** is the injection of a drug (anesthetic) that depresses neuron activity resulting in an inability to feel pain.



6. The spinal cord is held in place within the vertebral canal.
  - A. The spinal cord is anchored to the coccyx by connective tissue called the **filum terminale**.
  - B. The **denticulate ligaments** are connective tissue strands that connect the pia mater to the dura mater.

### Cross Section of the Spinal Cord

FIGURE 12.3

1. The spinal cord consists of peripheral white matter and central gray matter.
2. The spinal cord is divided into two halves by the anterior median fissure and the posterior median sulcus.
3. The white matter is myelinated axons.
  - A. Each half of the cord is divided into the **ventral** (anterior), **dorsal** (posterior), and **lateral columns** or **funiculi** (L. little cord; singular = funiculus).
  - B. Each funiculus is divided into **nerve tracts**, also called **fasciculi** (L. little bundles; singular = fasciculus) or pathways. The nerve tracts ascend or descend within the spinal cord. Each nerve tract has specific functions, such as carrying action potentials for pain sensations or controlling skeletal muscles.
  - C. The **white commissure** consists of myelinated axons that cross to the opposite side of the spinal cord.
4. The gray matter consists of neuron cell bodies, dendrites, and axons.
  - A. Each half of the gray matter has a **posterior** and **anterior horn**. In some parts of the spinal cord there is also a **lateral horn**.
  - B. The **gray commissure** consists of unmyelinated interneurons that cross to the opposite side of the spinal cord.
5. The **central canal** is a small space within the gray commissure. It is filled with cerebrospinal fluid and connects to spaces within the brain called ventricles.

6. Spinal nerves arise from rootlets that combine to form spinal nerve roots.
  - A. The **dorsal root** is formed by rootlets that arise near the posterior horn. Each dorsal root has a dorsal root ganglion.
  - B. The **ventral root** is formed by rootlets that arise near the anterior horn.
  - C. The dorsal and ventral roots combine to form a **spinal nerve**.

### Organization of Neurons in the Spinal Cord and Spinal Nerves

FIGURE 12.4

1. Sensory neurons.
  - A. The **dorsal root ganglia** within the dorsal roots contain the cell bodies of sensory neurons (unipolar neurons).
  - B. The dorsal root contains the axons of the sensory neurons. The axons from various parts of the body pass through spinal nerves into the dorsal roots and then into the spinal cord.
    - 1) Some of the sensory neuron axons synapse with the cell bodies of interneurons in the posterior horns.
    - 2) Some of the sensory neuron axons enter the white matter and ascend or descend as part of nerve tracts.
2. Motor neurons.
  - A. The cell bodies of motor neurons to skeletal muscles are in the anterior horns.
  - B. The cell bodies of motor neurons of the autonomic nervous system, which supplies smooth muscle, cardiac muscle, and glands, are in the lateral horns.
  - C. The ventral root contains the axons of motor neurons from the anterior and lateral horns.
3. Spinal nerves contain the axons of sensory and motor neurons.

### REFLEXES

FIGURE 12.5

1. A **reflex arc** is the smallest part of the nervous system that is capable of receiving a stimulus and producing a response. A **reflex** is the response produced by a reflex arc. A reflex arc can occur through the spinal cord or the brain.

2. Components of a reflex arc.
  - A. **Sensory receptor.** This can be the ending of a sensory neuron or a specialized cell associated with the ending of the sensory neuron. The sensory receptor produces an action potential in response to a stimulus.
  - B. **Sensory neuron.** This afferent neuron functions to carry the action potential to the CNS.
  - C. **Interneuron.** This neuron (or neurons) connects the sensory neuron to the motor neuron. Some reflexes do not have interneurons neurons.
  - D. **Motor neuron.** This efferent neuron functions to carry the action potential to the effector organ.
  - E. **Effector organ.** Muscle (skeletal, smooth, or cardiac) or glands that produce a response to the stimulus.
3. Characteristics of a reflex.
  - A. Reflexes help to maintain homeostasis, e.g., remove the hand from a painful stimulus; maintain balance, blood pressure, or blood carbon dioxide levels.
  - B. Reflexes produce the same response (more-or-less) each time.
  - C. A reflex does not require conscious thought. This does not mean, in some cases, that you are not aware that the reflex has occurred.
  - D. Reflexes are involuntary.

☞ Why is it advantageous to have a repeatable response that occurs on an unconscious level?

## Stretch Reflex

FIGURE 12.6

1. The **muscle spindle** is the sensory receptor of the stretch reflex. Muscle spindles are scattered throughout skeletal muscles.
  - A. The muscle spindle consists of three to 10 small skeletal muscle fibers.
  - B. The center of these muscle fibers cannot contract. When they are stretched, action potentials are generated in the attached sensory neurons.

2. The **stretch reflex** arc consists of the muscle spindle, a sensory neuron, an alpha motor neuron, and the muscle.
  - A. Type A fibers can be divided into alpha, beta, gamma, and delta fibers. The fibers decrease in size, with the alpha fibers being the largest and the delta fibers the smallest.
  - B. Note that there is no interneuron between the sensory neuron and the alpha motor neuron.
  - C. The alpha motor neuron is the neuron forming a motor unit.
3. Operation of the stretch reflex.
  - A. Stretch of the muscle causes stretch of the muscle spindle.
  - B. Action potentials travel by the sensory neuron to the spinal cord in which action potentials are generated in the alpha motor neuron.
  - C. The alpha motor neuron carries action potentials to the neuromuscular junction, causing an action potential in the muscle and contraction of the muscle.
4. Function of the stretch reflex.
  - A. The stretch reflex acts to maintain the length of the muscle. When the length of the muscle increases, the reflex causes increased muscular contraction that resists the stretch.
  - B. The stretch reflex is important for maintaining posture and the position of body parts (e.g., holding the hands in a fixed position while threading a needle).
5. Muscle spindles are important sensory receptors that provide the brain with information about the tension in muscles and the length of muscles.
  - A. Collateral branches from the sensory neuron enter nerve tracts and go to the brain.
  - B. Some of the sensory information is at a conscious level, so we are aware of where different parts of our bodies are and what they are doing.
  - C. Some of the sensory information is at an unconscious level and is used to better coordinate muscle activities.

### **Golgi Tendon Reflex**

FIGURE 12.7

1. Structure of the Golgi tendon reflex arc.
  - A. The **Golgi tendon organ** is a fibrous capsule crossed with bundles of collagen fibers. One end of the collagen bundles is continuous with tendons, whereas the other end is attached to muscle fibers.
  - B. The endings of sensory neurons are wrapped around the collagen bundles of the Golgi tendon organ.

- C. The sensory neuron synapses with an inhibitory interneuron in the spinal cord.
  - D. The inhibitory interneuron synapses with an alpha motor neuron.
  - E. The alpha motor neuron extends back to the muscle.
2. Operation of the Golgi tendon reflex.
- A. The alpha motor neuron is stimulated through descending nerve tracts from the cerebral cortex causing the muscle to contract.
  - B. Tension produced by the contracting muscle fibers stimulates the sensory neuron and an action potential is conducted to the inhibitory interneuron.
  - C. The inhibitory interneuron inhibits the alpha motor neuron, stimulation of the muscle stops, and the muscle relaxes.
3. Function of the Golgi tendon reflex.
- A. When great tension is applied to the tendon the Golgi tendon reflex causes the muscle to relax, protecting the tendon and the muscle from damage.
  - B. An example of the Golgi tendon reflex in action occurs when a weight lifter suddenly drops a weight while straining to lift it.
  - C. An example of the Golgi tendon reflex failing to provide protection is a pulled hamstring.
4. Golgi tendon organs are important sensory receptors that provide the brain with information about the tension in muscles.
- A. Collateral branches from the sensory neuron enter nerve tracts and go to the brain.
  - B. Some of the sensory information is at a conscious level and some is at an unconscious level.

### **Withdrawal Reflex**

FIGURE 12.8

1. Structure of the withdrawal reflex arc.
- A. The free nerve endings of sensory neurons function as pain receptors.
  - B. The sensory neuron synapses with an excitatory interneuron in the spinal cord.
  - C. The excitatory interneuron synapses with an alpha motor neuron.
  - D. The alpha motor neuron extends back to a muscle.

2. Operation of the withdrawal reflex.
  - A. Pain stimuli (e.g., tissue destruction) result in action potentials being conducted by the sensory neuron to the excitatory interneuron.
  - B. The excitatory interneuron stimulates the alpha motor neuron resulting in contraction of the muscle (usually a flexor muscle).
3. Function of the withdrawal reflex.
  - A. The withdrawal reflex removes a body part from a painful stimulus, thus preventing further damage.
  - B. An example would be stepping on a tack.
4. Other events that occur with the withdrawal reflex.
  - A. The sensory neurons have collateral branches that synapse with ascending interneurons.
  - B. The interneurons carry information about the painful stimulus to the cerebral cortex and conscious awareness of the painful stimulus occurs.

### **Reciprocal Innervation**

FIGURE 12.9

1. Structure of reciprocal innervation arc.
  - A. Collateral branches from the sensory neuron in the withdrawal reflex synapses with an inhibitory interneuron.
  - B. The inhibitory interneuron synapses with an alpha motor neuron that supplies the antagonist of the muscle in the withdrawal reflex.
2. Operation of reciprocal innervation.
  - A. The pain stimuli that initiates the withdrawal reflex also initiates reciprocal innervation.
  - B. The antagonist muscle is inhibited.
3. Function of reciprocal innervation.
  - A. When the muscles that cause withdrawal are contracting their antagonist are relaxing. Therefore the two muscle groups don't act against each other.
  - B. An example would be contraction of the hamstrings (flexors of the leg) accompanied by relaxation of the quadriceps femoris (extensors of the leg).



## Crossed Extensor Reflex

FIGURE 12.10

1. Structure of the crossed extensor reflex arc.
  - A. Collateral branches from the sensory neuron in the withdrawal reflex synapses with interneurons that cross through the white commissure to the opposite side of the spinal cord.
  - B. The interneuron synapses with an alpha motor neuron that supplies the extensor muscles of the opposite leg.
2. Operation of the crossed extensor reflex.
  - A. Initiation of the withdrawal reflex results in action potentials that cross to the opposite side of the spinal cord through the interneuron.
  - B. The alpha motor neuron is stimulated and the extensor muscle contracts.
3. Function of the crossed extensor reflex.
  - A. When one limb is withdrawn from a painful stimulus the other limb extends or tenses to prevent falling.
  - B. An example would be stepping on a tack.

## SPINAL PATHWAYS

FIGURE 12.11

1. Reflexes do not operate as isolated entities within the nervous system.
2. Divergent pathways from the reflex arc allow conscious and unconscious input to the brain.
3. Convergent pathways control the output of motor neurons.
  - A. Motor neurons can be controlled through the reflex arc.
  - B. Motor neurons can be controlled by the brain.
    - 1) Voluntary control, such as causing a skeletal muscle to contract, is possible.
    - 2) Involuntary control, such as maintaining muscle tone, is possible.
    - 3) Descending pathways from the brain can affect the degree of excitability of the neurons in the spinal cord. Thus, the brain can increase or decrease reflex responses.

4. **Spinal shock** is the loss of reflex responses below the site of injury to the spinal cord.
  - A. The brain normally facilitates the motor neurons of many reflex arcs.
  - B. Following spinal cord injury, the connection to the brain is severed. Motor neurons are no longer facilitated, so their resting membrane potentials are so far from threshold that they are unresponsive. Thus, reflex activity below the level of the injury is lost.
  - C. Skeletal muscle reflexes are lost because of spinal shock. After a few weeks to a few months they may return. Stretch reflexes, flexor reflexes, postural antigravity, and stepping reflexes return in the order listed.
  - D. Reflexes regulating blood pressure are lost and blood pressure can drop to as low as 40 mm Hg. Sacral reflexes controlling bladder and colon emptying are lost, but return after a few weeks.

## STRUCTURE OF PERIPHERAL NERVES

FIGURE 12.12

1. A **nerve** is a collection of axons, Schwann cells, and connective tissue in the PNS.
2. The axons are organized by the connective tissue.
  - A. The **endoneurium** surrounds individual nerve fibers (axons) and their associated Schwann cells.
  - B. The **perineurium** surrounds groups of nerve fibers called **nerve bundles** or **fascicles**.
  - C. The **epineurium** surrounds the whole nerve (groups of nerve bundles).

## SPINAL NERVES

1. There are 31 pairs of spinal nerves which leave the spinal cord and pass through the intervertebral foramina.

FIGURE 12.13

- A. Eight pairs of cervical (C) spinal nerves.
  - B. Twelve pairs of thoracic (T) spinal nerves.
  - C. Five pairs of lumbar (L) spinal nerves.
  - D. Five pairs of sacral (S) spinal nerves.
  - E. One pair of coccygeal (CO) spinal nerves.
2. The spinal nerves are often denoted by a letter and a number. The numbering always starts with the most superior spinal nerve in a group. For example, T1 is the first thoracic spinal nerve.

3. The distribution of spinal nerves to the skin is called a **dermatomal map**. A dermatome is the area of skin supplied by a pair of spinal nerves.

FIGURE 12.14

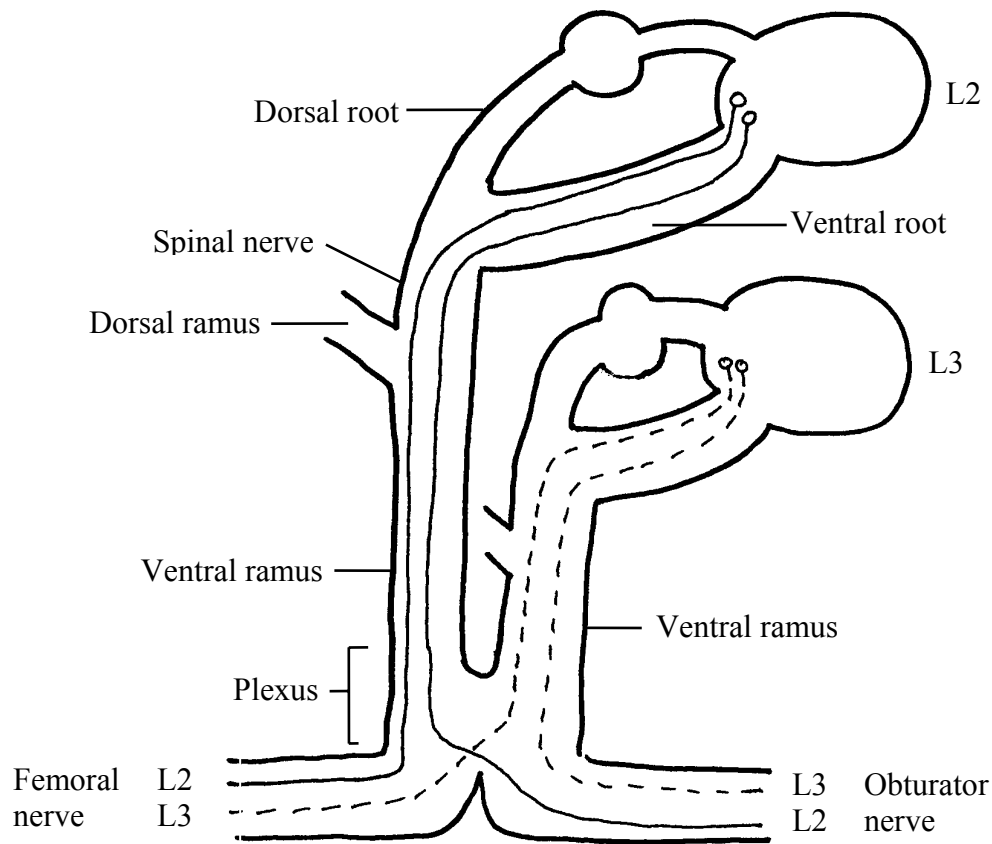
- A. Although dermatomal maps are usually drawn as though each dermatome was distinct from other dermatomes, there is actually overlap between dermatomes.
- B. Dermatomes can be used to determine the level of a spinal cord injury.
- ☞ If the victim of an automobile accident lost the sense of sensation inferior to the knee, where was the spinal cord injured?

4. Shortly after the dorsal and ventral roots combine to form a spinal nerve, the spinal nerve splits into two **rami** (L. branch; singular = ramus).

FIGURE 12.15

- A. The dorsal rami supply the skin of the back and the muscles of the back that move the vertebral column.
- B. The ventral rami of the thoracic spinal nerves form the **intercostal nerves** (between the ribs).
- C. The ventral rami of the cervical, lumbar, sacral, and coccygeal spinal nerves give rise to **plexuses** (L. a braid; singular = plexus), which are an intermingling of the spinal nerves..

D. The plexuses give rise to nerves that are distributed to the rest of the body. Note that these nerves contain axons from more than one level of the spinal cord.



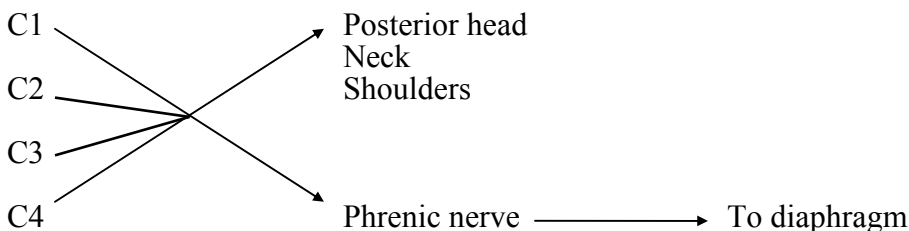
**Cervical Plexus**

1. The cervical **plexus** is formed from spinal nerves C1 to C4.

FIGURE 12.16

2. The cervical plexus supplies the skin of the posterior head, the neck, and the shoulders (the anterior part of the head is supplied by the trigeminal nerve, a cranial nerve).

3. The phrenic nerve (C3 to C5) supplies the diaphragm.



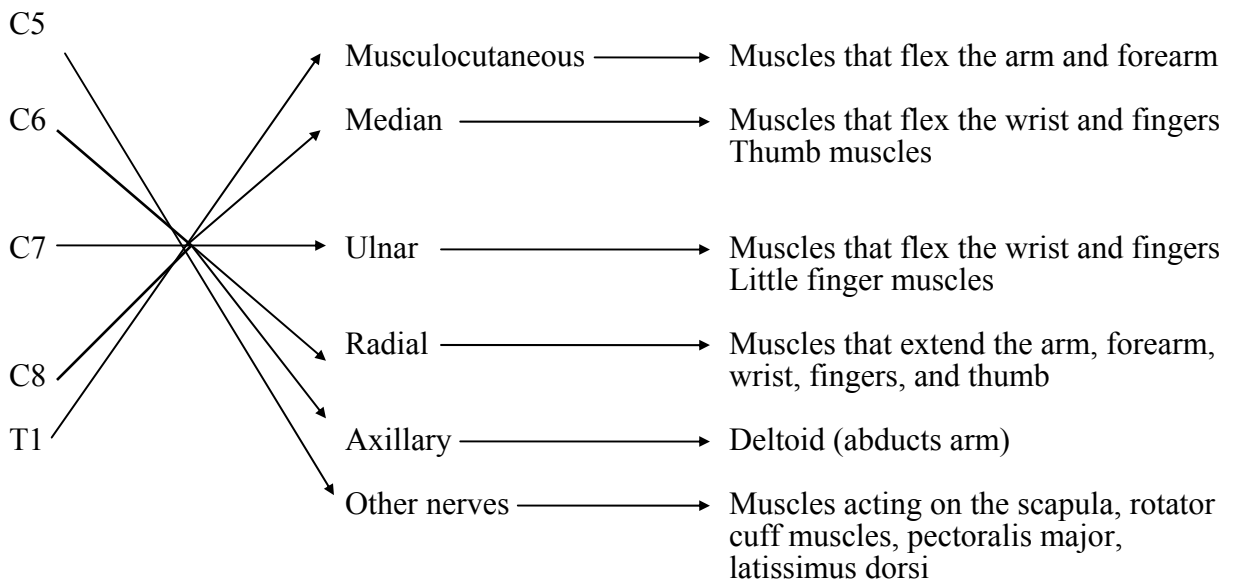
- ☞ Explain why spinal cord injury superior to C5 can result in respiratory failure, whereas injury at or inferior to C5 does not.

### Brachial Plexus

1. The **brachial plexus** is formed from spinal nerves C5 to T1.

FIGURES 12.17 - 12.22

2. As the ventral rami pass through the plexus they form three **trunks**, which separate into six **divisions**. The divisions join together to form the posterior, lateral, and medial **cords**. **Five** major nerves arise from the cords.
3. The brachial plexus supplies the skin of the upper limbs.
4. Although there are some exceptions, we will group the muscle innervation of the brachial plexus nerves as follows:



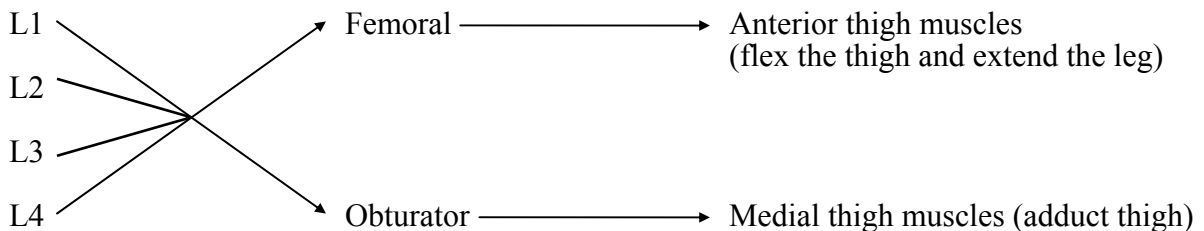
5. **Brachial anesthesia** results in loss of sensation in the upper limb. It is accomplished by injecting an anesthetic into the brachial plexus.

## Lumbar and Sacral Plexuses

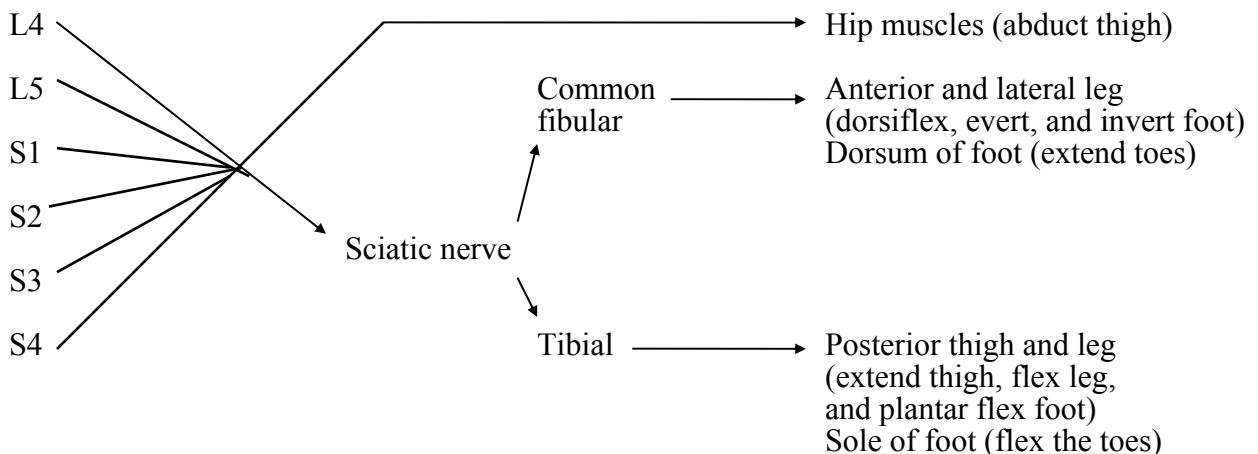
1. The **lumbar** and **sacral plexuses** are often considered a single plexus, the **lumbosacral plexus**.

FIGURES 12.23 - 12.27

2. The lumbar plexus is formed from spinal nerves L1 to L4.
  - A. The lumbar plexus supplies the skin of the anterior and medial thigh, and the medial leg.
  - B. The lumbar plexus supplies the muscles of the anterior and medial thigh.



3. The sacral plexus is formed by spinal nerves L4 to S4.
  - A. The sacral plexus supplies the skin of the posterior thigh, the leg (except for the medial surface), and the foot.
  - B. The sacral plexus supplies the muscles of the hip, posterior thigh, and leg.
  - C. The major nerve arising from the sacral plexus is the sciatic nerve. The sciatic nerve is two nerves bound together. At the knee the sciatic nerve separates into the common fibular and tibial nerves.



4. Pressure on the sciatic nerve from a herniated disk can produce painful sensations in the lower limb.



## Brachial Plexus

<u>Nerve Innervation</u> (Origin)	<u>Muscle Innervated</u>	<u>Movement</u>	<u>Cutaneous</u>
<b>Axillary</b> (C5-C6)	Deltoid	Abducts arm	Inferior lateral shoulder
	Teres minor	Laterally rotates arm	
<b>Radial</b> (C5-T1)	Triceps brachii	Extends forearm	Posterior surface of arm and forearm; lateral two thirds of dorsum of hand
	Brachialis (part) Brachioradialis	Flexes forearm	
	Supinator	Supinates forearm	
	Posterior forearm muscles	Extend wrist Abduct and adduct wrist Extend fingers Extend and abduct thumb	
<b>Musculocutaneous</b> (C5-C7)	Coracobrachialis	Flexes arm	Lateral surface of forearm
	Biceps brachii Brachialis (most)	Flexes forearm	
	Biceps brachii	Supinates forearm	
<b>Ulnar</b> (C8-T1)	Anterior forearm muscles	Flex and adduct wrist Flex distal phalanges of little and ring finger	Medial one third of hand, little finger, and medial half of ring finger
	Intrinsic hand muscles	Adduct thumb Abduct and adduct fingers Oppose, flex, and abduct little finger	
<b>Median</b> (C5-T1)	Pronators	Pronate forearm	Lateral two thirds of palm of hand; anterior surface of thumb, index, and middle fingers; dorsal tips of thumb, index, and middle fingers
	Anterior forearm muscles	Flex and abduct wrist Flex distal phalanges of middle and index fingers Flex middle and proximal phalanges Flex thumb	
	Thenar muscles	Oppose, flex, and abduct thumb	



## Lumbosacral Plexus

<u>Nerve Innervation</u> (Origin)	<u>Muscle Innervated</u>	<u>Movement</u>	<u>Cutaneous</u>	
<b>Obturator</b> (L2-L4)	Medial thigh muscles	Adduct thigh	Superior medial side of thigh	
<b>Femoral</b> (L2-L4)	Sartorius	Flexes thigh Flexes leg	Anterior and lateral thigh, medial leg and foot	
	Rectus femoris	Flexes thigh Extends leg		
	Vastus lateralis Vastus medialis Vastus intermedius	Extend leg		
<b>Tibial</b> (L4-S3)	Biceps femoris (long head) Semitendinosus Semimembranosus	Extend thigh Flex leg	Posterior surface of leg and sole of foot	
	Gastrocnemius Soleus	Plantar flex the foot		
	Posterior extrinsic foot muscles	Invert the foot Flex the toes		
	Intrinsic foot muscles	Flex, extend, abduct, and adduct the toes		
	<b>Common fibular</b> (L4-S2)	Biceps femoris (short head) Anterior extrinsic foot muscles		Flexes leg Dorsiflex, invert, and evert foot Extend toes
		Lateral extrinsic foot muscles		Plantar flex and evert foot