

# Brain and Cranial Nerves

## Chapter 13

### MAJOR PARTS OF THE BRAIN

FIGURE 13.1 and TABLE 13.1
----------------------------

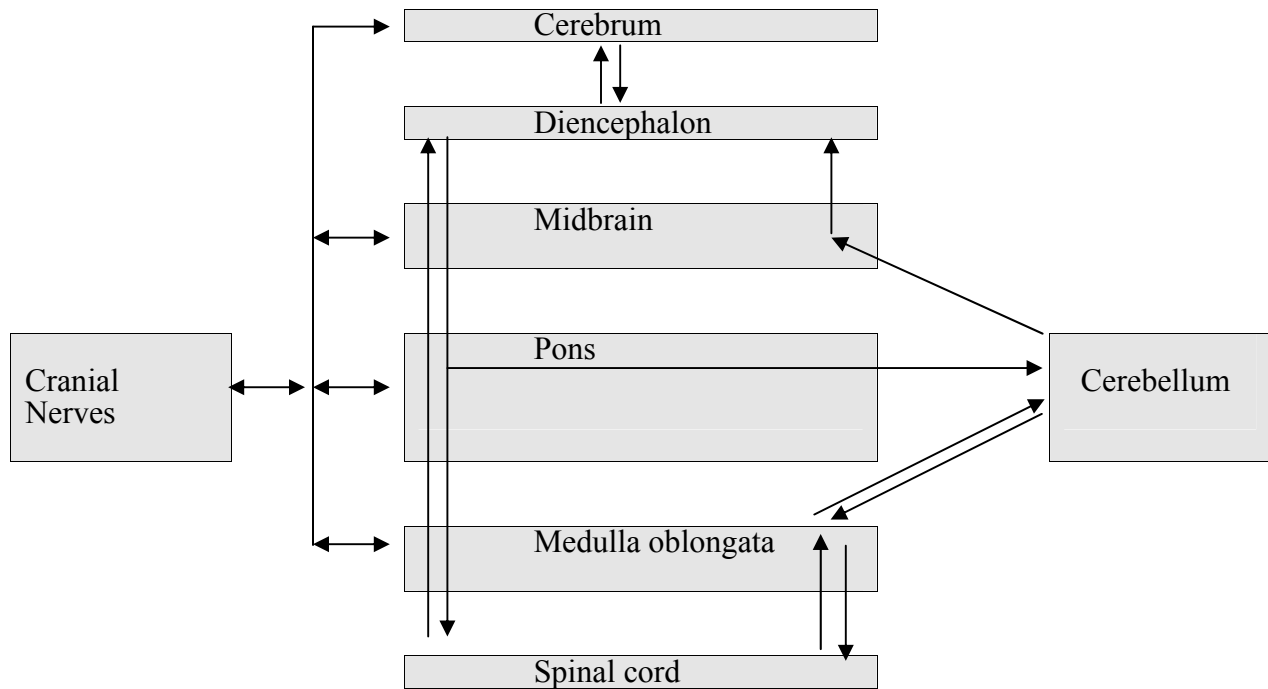
1. The spinal cord merges with the brainstem at the foramen magnum.
2. From inferior to superior, the **brain stem** consists of the **medulla oblongata** (L. a soft structure in the center of a part; longer than wide), **pons** (L. bridge; located between the medulla oblongata and the midbrain), and **midbrain**.
3. The **cerebellum** is attached to the posterior surface of the brainstem.
4. The **diencephalon** rests on top of the brainstem.
5. The **cerebrum** surrounds the diencephalon and the superior parts of the brainstem and cerebellum. It is like the cap of a mushroom

### BRAIN STEM

FIGURES 13.2
--------------

#### Functions of the Brainstem

1. The brainstem connects parts of the nervous system.
  - A. **Cranial nerves** arise from the brain and connect it to the head, neck, and organs of the thoracic and abdominopelvic cavities.
  - B. **Ascending nerve tracts** from the spinal cord and cranial nerves pass through the brainstem to the diencephalon or the cerebellum. Nerve tracts from the cerebellum also ascend through the brainstem.
  - C. **Descending nerve tracts** from the cerebrum and diencephalon pass through the brainstem to the spinal cord, pass out cranial nerves, or extend to the cerebellum. Nerve tracts from the cerebellum also connect to the spinal cord.



2. Integration and reflexes. The brainstem is more than a conduit for nerve tracts. It contains many nuclei with sensory and motor functions.
  - A. Nuclei in the medulla oblongata are involved in regulating vital body functions such as heart rate, blood vessel diameter, and breathing. Damage to small areas of the medulla oblongata can cause death, whereas damage to large areas of the cerebrum or cerebellum often do not cause death.
  - B. Brainstem nuclei are part of systems controlling muscles and glands through cranial and spinal nerves. For example, swallowing, vomiting, hiccuping, coughing, sneezing, chewing, moving the tongue, moving the eyes, facial expressions in response to emotions, moving the limbs, maintaining posture, contracting of the wall of the digestive tract, secretion of glands in the digestive tract, and many more.
  - C. Brainstem nuclei are part of an arousal system that maintains consciousness.

### Organization of the Brainstem

1. The brainstem has posterior and anterior parts. Here is the big picture of the organization.
  - A. The posterior part is nuclei and (mostly) ascending nerve tracts.
    - 1) Cranial nerve nuclei
    - 2) Reticular formation.
    - 3) Corpora quadrigemina
  - B. The anterior part is descending nerve tracts and some nuclei.
    - 1) Cerebral peduncles
    - 2) Substantia nigra

2. The posterior part of the brainstem is called the **tegmentum**. It has three parts consisting of nuclei and nerve tracts that form columns extending the length of the brainstem.

FIGURE 13.2c

- A. Cranial nerve nuclei.
    - 1) **Sensory cranial nerve nuclei** receive input from the cranial nerves. These nuclei are comparable to the posterior horn of the spinal cord gray matter.
    - 2) **Motor cranial nerve nuclei** contain the cell bodies of the motor neurons that exit the brainstem through cranial nerves. These nuclei are comparable to the anterior horn of the spinal cord gray matter.
  - C. The **reticular formation** is a collection of nuclei and nerve tracts that form the core of the tegmentum.
    - 1) Some functions of reticular formation nuclei.
      - a. Integration of cranial nerve reflexes. That is, the reticular formation nuclei connect to and interact with the cranial nerve nuclei.
      - b. Autonomic nervous system control of organs. For example, nuclei in the medulla oblongata control vital functions such as heart rate, blood vessel diameter, and breathing. Pontine nuclei are also involved with breathing.
      - c. Some of the nuclei form the **reticular activating system**, which interacts with higher areas of the brain to maintain consciousness or to induce sleep. Depression of the reticular activating system can lead to coma (injury), unconsciousness (general anesthesia, barbiturates), or sleep.
  - D. Most of the nerve tracts are ascending tracts from the spinal cord, cranial nerves, or cerebellum, but some are descending tracts involved with motor functions tracts] or pain sensations.
3. The midbrain has an additional posterior part called the **tectum** or the **corpora quadrigemina** (L. four-twin bodies, i.e., two pairs of twins). The corpora quadrigemina is four mounds on the posterior midbrain, divided into the superior and inferior colliculi.

FIGURE 13.2b and 13.3

- A. The **superior colliculi** (L. a little hill) are involved with vision and visual reflexes, e.g., visual tracking of objects.
- B. The **inferior colliculi** are involved with hearing and auditory reflexes, e.g., turning the head in the direction of a loud sound.

- C. The corpora quadrigemina is more complex than a simple reflex center and acts to modify and integrate visual and auditory input.
- 4. The anterior part of the brainstem consists of descending tracts and nuclei. Most of the fibers in these tracts connect to nuclei in the pons, to cranial nerve nuclei, or to reticular formation nuclei. Some of the fibers continue through the brainstem to the spinal cord.

FIGURE 13.3

- A. The **cerebral peduncles** form the anterior surface of the midbrain, and they contain descending nerve [corticospinal and rubrospinal] tracts controlling voluntary skeletal muscle activity.
- B. Dysfunction of the **substantia nigra**, a nucleus in the midbrain, results in Parkinson's disease.
- C. In the pons, about 5% of the descending motor fibers from the cerebral peduncles continue on to the medulla oblongata. Most of these motor fibers connect to pontine nuclei that connect to the cerebellum.
- D. The **pyramids** are two raised areas on the anterior surface of the medulla oblongata formed by the descending motor fibers from the pons. Most of the nerve fibers in these tracts **decussate** (cross over) in the medulla oblongata and pass on to the spinal cord. Therefore the left side of the brain controls (mostly) the muscular activity of the right side of the body, and vice versa.

FIGURE 13.2a

## CEREBELLUM

FIGURE 13.4

- 1. The **cerebellum** (L. little brain) is organized like the cerebrum. The cerebellum forms 10% of the brain's volume but contains over half of the brain's neurons.
  - A. Gray matter forms a cerebellar cortex and nuclei within the cerebellum. The surface of the cerebellum has many shallow **fissures** and raised areas called **folia** [L. leaf; sing., folium]. Deeper fissures divide the cerebellum into lobes.
  - B. White matter.
    - 1) Within the cerebellum the nerve tracts are collectively called the **arbor vitae** (tree of life).

- 2) The cerebellum is connected to the brain stem by nerve tracts: the **inferior cerebellar peduncles** connect to the medulla oblongata, the **middle cerebellar peduncles** connect to the pons, and the **superior cerebellar peduncles** connect to the midbrain.
2. The cerebellum has three parts: two large **lateral hemispheres**, the **vermis** (L. worm-shaped), which is located between the lateral hemispheres, and a small **flocculonodular** (L. a tuft of wool) **lobe** on the inferior surface.
3. The cerebellum is very important for motor function. Acting with other parts of the brain, the cerebellum is involved in the control of balance, posture, locomotion, and fine motor control. It is also involved in the planning, practicing, and learning of complex movements.

## DIENCEPHALON

FIGURE 13.5

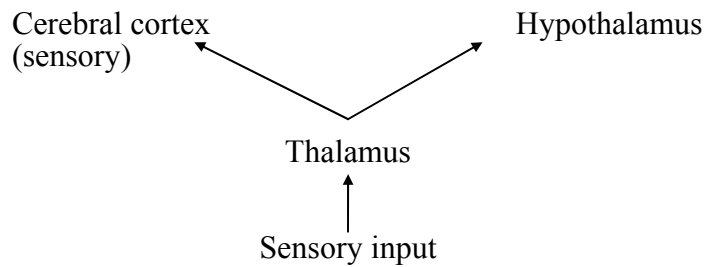
1. The **diencephalon** (G. through the brain) is located on top of the brain stem and is covered by the cerebrum.
2. The main components of the diencephalon are the thalamus, subthalamus, hypothalamus, and epithalamus.

## Thalamus


FIGURE 13.5b

1. The **thalamus** (G. inner room) makes up approximately 80% of the diencephalon. It has a left and right lobe connected by the **interthalamic adhesion** or **intermediate mass**.  
Analogy: the thalamus is like a yo-yo.
2. The thalamus is a cluster of nuclei that function as relay and integration centers for both ascending and descending nerve tracts.

A. Almost all sensory input (olfaction is an exception) passes through the thalamus.



B. The thalamus is a relay center for nerve tracts involved with skeletal motor activity.



C. The thalamus is part of the limbic system, which is responsible for emotions (more later).

### Subthalamus

1. The **subthalamus** is located inferior to the thalamus.
2. The subthalamus is involved with controlling motor functions.

### Epithalamus

1. The **epithalamus** is located superior and posterior to the thalamus.
2. As part of the limbic system, the epithalamus is involved with the emotional reactions to odors.
3. The **pineal body** (L. shaped like a pine cone) is part of the epithalamus. It produces a hormone (melatonin) that may be involved with the onset of puberty (more next semester) and with sleep/wake cycles (biological clock).

### Hypothalamus

FIGURE 13.5c

1. The **hypothalamus** is the most inferior part of the diencephalon.
2. Parts and their functions.
  - A. The **mamillary bodies** (L. nipple) are nuclei involved with olfactory reflexes and emotional responses to odors.

- B. The **infundibulum** (L. funnel) is a funnel-shaped extension from the hypothalamus to the pituitary gland. The hypothalamus can regulate the activities of the pituitary gland through the infundibulum. Because the pituitary gland produces many hormones with diverse effects this means the hypothalamus is an important part of the endocrine system.
- C. The rest of the hypothalamus affects a variety of functions.
- 1) There are centers for hunger, satiety [sa-tī'e-tē] (feeling full), thirst, and temperature regulation.
  - 2) The hypothalamus affects the activities of ANS centers in the brainstem and spinal cord, producing changes in heart rate, movement of food through the digestive tract, and emptying of the urinary bladder.
  - 3) The hypothalamus coordinates the sleep/wake cycle (biological clock).
  - 4) The hypothalamus plays a role in many emotional responses, e.g., fear, rage, pain, pleasure, and sex drive.

## CEREBRUM

FIGURE 13.6

1. Surface anatomy.
  - A. The surface of the cerebrum is folded into convolutions which greatly increase its surface area. The rounded ridges are called **gyri** (singular = gyrus) and grooves called **sulci** (singular = sulcus). Deep grooves are called **fissures**.
  - B. The cerebrum is divided into right and left hemispheres by the **longitudinal fissure**.
  - C. The pattern of gyri, sulci, and fissures can be used to divide the surface of each cerebral hemisphere into regions that correspond to the overlying bones.
    - 1) The **central sulcus** separates the **frontal** and **parietal lobes**.
    - 2) The **lateral fissure** separates the **temporal lobe** from the frontal and parietal lobes.
    - 3) The **occipital lobe** forms the posterior part of the cerebrum.
    - 4) The **insula** is a lobe found buried within the lateral fissure.

D. General functions of the cerebral lobes:

Frontal	Voluntary motor function, motivation, and smell (olfactory bulbs)
Parietal	Evaluation of most sensory input (except smell, hearing, and vision)
Occipital	Vision
Temporal	Smell, hearing, memory, abstract thought, and judgment
Insula	Visceral motor (belching, gastric movements) and visceral sensory (nausea and "abdominal sensations"); a poorly understood lobe

2. Gray and white matter.

FIGURE 13.7

A. Gray matter forms the **cortex** (outer surface) and **nuclei** (deep within the cerebrum).

B. White matter, called the **cerebral medulla**, forms nerve tracts.

- 1) **Association fibers** connect areas of the cerebral cortex within the same hemisphere. The **fornix** is an example.
- 2) **Commissural fibers** connect one cerebral hemisphere with the other cerebral hemisphere. The largest commissural tract is the **corpus callosum**.
- 3) **Projection fibers** connect the cerebrum with other parts of the brain and spinal cord. Motor tracts from the cerebrum and sensory tracts to the cerebrum are examples.

**Basal Nuclei**

FIGURE 13.8

1. The **basal nuclei** are a group of nuclei found in the cerebrum (corpus striatum), diencephalon (subthalamic nucleus), and midbrain (substantia nigra).
2. The basal nuclei are involved with control of motor function.



## Limbic System

FIGURE 13.9

1. The **limbic system** is an imprecisely defined portion of the cerebrum and diencephalon. Limbus means border, and the term limbic refers to a ring of tissue at the junction of the diencephalon and cerebrum.
2. The limbic system is involved with emotions and memory.

## MENINGES AND CEREBROSPINAL FLUID

### Meninges

FIGURE 13.10

1. The brain and spinal cord are surrounded by bone and membranes called the **meninges** (L. membrane; meninx = singular). They provide protection and the meninges help to hold the brain and spinal cord in place.
2. **Dura mater** (L. hard mother).
  - A. The dura mater is the strongest, thickest of the meninges, and holds the brain firmly in place.
  - B. The dura mater is continuous with the periosteum of the cranial cavity.
  - C. The dura mater has folds that extend into brain fissures and help to hold the brain in place.
    - 1) The **falx cerebri** separates the cerebral hemispheres and attaches to the crista galli.
    - 2) The **falx cerebelli** separates the cerebellar hemispheres.
    - 3) The **tentorium cerebelli** separates the cerebrum from the cerebellum.
  - D. The dura mater separates in some places to form the **dural venous sinuses**, which are filled with blood. They drain blood and cerebrospinal fluid from the brain.
  - E. The **subdural space** is a small space deep to the dura mater that is filled with serous fluid. Damage to the meninges and brain can result in bleeding into the subdural space. The resulting accumulation of blood is called a **subdural hematoma**.
3. **Arachnoid mater** (L. spider-like).
  - A. The arachnoid mater is a delicate, cobwebby membrane beneath the dura mater. The arachnoid mater adheres to the brain and spinal cord but does not dip into the sulci or fissures, except for the longitudinal fissure. The arachnoid is separated from the dura mater by the subdural space.

- B. Deep to the arachnoid, the **subarachnoid space** is filled with cerebrospinal fluid and blood vessels.
- 4. **Pia mater** (L. tender mother).
  - A. The pia mater is the innermost meninx, a delicate membrane with many blood vessels.
  - B. The pia mater adheres to the surface of the brain and spinal cord.

## Ventricles

FIGURE 13.11

1. The brain and spinal cord start out as a hollow tube. The walls of the tube become brain and spinal cord tissue and the hollow part of the tube becomes the ventricles and central canal of the spinal cord.
2. There are two **lateral ventricles**, one in the left cerebral hemisphere and one in the right cerebral hemisphere. They are separated by two thin membranes, the **septa pellucida** (L. transparent wall), which are usually fused together at the midline.
3. Each lateral ventricle connects to the **third ventricle** by an **interventricular foramen** (foramen of Monroe).
4. The third ventricle is located between the lobes of the thalamus and surrounds the intermediate mass. Analogy: if the thalamus is like a yo-yo, then the third ventricle is the space where the string is located.
5. The third ventricle connects to the fourth ventricle by an **cerebral aqueduct** (aqueduct of Sylvius).
6. The **fourth ventricle** is located between the brain stem and the cerebellum.
  - A. The fourth ventricle continues on as the **central canal** of the spinal cord.
  - B. The fourth ventricle opens into the subarachnoid space by two **lateral apertures** and the **median aperture**

## Cerebrospinal Fluid

FIGURE 13.12

1. **Cerebrospinal fluid (CSF)** is produced by the choroid plexuses. The **choroid plexuses** consists of ependymal cells and blood vessels and are found lining parts of all four ventricles.
2. CSF is similar to blood plasma and functions to cushion the brain and to transport gases, nutrients, etc.

3. Circulation of CSF.
  - A. CSF is produced by the choroid plexuses from blood.
  - B. Lateral ventricle - interventricular foramen - third ventricle - cerebral aqueduct - fourth ventricle - lateral and median apertures - subarachnoid space - **arachnoid granulations** (extensions of the arachnoid into the dural sinuses) - dural sinuses - back to the blood.
  - C. From the fourth ventricle CSF goes down the central canal of the spinal cord and comes back up the central canal as well.
4. Interference of CSF flow or build up of CSF can produce pressure that damages the brain.
  - A. In **internal hydrocephalus** CSF accumulates in the ventricles.
  - B. In **external hydrocephalus** CSF accumulates in the subarachnoid space.

### **BLOOD SUPPLY TO THE BRAIN**

1. Although the brain is only 2% of the body's weight it receives 15% - 20% of the blood pumped by the heart. Disruption of the blood supply for a few seconds can cause unconsciousness, and for a few minutes can cause irreversible damage.
2. The **blood-brain barrier** is formed by the epithelial cells of capillaries in the brain. The cells are joined together by tight junctions, which prevent substances from passing between the cells. Astrocytes influence the formation of the blood brain barrier.
  - A. The blood-brain barrier controls what substances can enter the central nervous system.
    - 1) Lipid-soluble substances diffuse across the blood-brain barrier. Glucose and amino acids are actively transported into the central nervous system.
    - 2) Large water-soluble molecules and charged molecules do not diffuse across. Therefore proteins and many potentially toxic substances cannot enter the central nervous system.
  - B. A clinical example of the blood-brain barrier in action.
    - 1) Parkinson's disease results from an inadequate production of a neurotransmitter in the brain called dopamine.
    - 2) A possible treatment would be to administer dopamine. However, dopamine does not cross the blood-brain barrier.
    - 3) The solution is to administer L-Dopa, which can cross the blood-brain barrier. Once in the brain, L-Dopa is converted into dopamine.

## DEVELOPMENT

FIGURE 13.13

1. The CNS develops from the **neural plate**, which is ectoderm on the posterior surface of the embryo.
  - A. The **neural folds** rise up as waves from the neural plate. The **neural crests** are the tops of the neural folds. Some of the neural crest cells separate from the neural crest to form parts of the PNS.
  - B. The neural folds come together to form the **neural tube**.
2. The superior end of the neural tube develops pouches called the forebrain, midbrain, and hindbrain. The remainder of the neural tube becomes the spinal cord.

FIGURE 13.14

- A. The wall of the neural tube gives rise to the tissues of the brain and spinal cord.
- B. The lumen (space) of the neural tube becomes the ventricles in the brain and the central canal in the spinal cord.

## CRANIAL NERVES

1. There are twelve pairs of cranial nerves. They are denoted by Roman numerals or by a specific name. For example, cranial nerve I is the olfactory nerve.
2. The cranial nerves arise from nuclei in the brain and exit the skull through foramina.
3. The cranial nerves supply structures of the head and neck. In addition, cranial nerve X, the vagus nerve, supplies the organs of the thoracic and abdominopelvic cavities.

FIGURE 13.15

### Types of Cranial Nerves by Function

1. **Sensory functions** include the special senses such as vision as well as general sensory functions such as touch and pain.
2. **Somatic motor functions** refer to control of skeletal muscles. Actually motor nerves have two components.
  - A. The somatic motor component consists of motor neurons that innervate skeletal muscle.
  - B. The proprioceptive component provides information about body position (e.g., muscle spindle and Golgi tendon organ). Although this is a sensory function, because it is so intimately tied to muscle function it is considered part of motor function.

3. **Parasympathetic function** (part of the autonomic nervous system) involves the regulation of cardiac muscle, smooth muscle, and glands.

See Table 13.5 for  
illustrations of the nerves

Nerve	Name Mnemonic	Function Mnemonic	Function
I Olfactory	<u>O</u> ld	Some	Smell
II Optic	<u>O</u> pie	Say	Vision
III Oculomotor	<u>O</u> ccasionally	Marry	Extrinsic eye muscles Parasympathetic: Intrinsic eye muscles (iris for light; ciliary body for focusing)
IV Trochlear	<u>T</u> ries	Money	Extrinsic eye muscle
V Trigeminal	<u>T</u> rigonometry	But	Sensory from face, nasal and oral cavities Muscles of mastication
VI Abducens	<u>A</u> nd	My	Extrinsic eye muscle
VII Facial	<u>F</u> eels	Brother	Sense of taste (ant. 2/3 tongue) Muscles of facial expression Parasympathetic: Salivary (submandibular and sublingual) and lacrimal glands
VIII Vestibulocochlear	<u>V</u> ery	Say	Hearing and balance
IX Glossopharyngeal	<u>G</u> loomy	Bad	Sense of taste (post. 1/3 tongue) Sensory for blood pressure and blood gases Swallowing muscles Parasympathetic: Salivary (parotid) glands
X Vagus	<u>V</u> ague	Business	Sensory from pharynx and larynx Swallowing muscles and voice production muscles Parasympathetic: Thoracic and abdominal organs
XI Accessory	<u>A</u> nd	Marry	Trapezius, sternocleidomastoid, and swallowing muscles
XII Hypoglossal	<u>H</u> ypoactive	Money	Tongue muscles

A **mnemonic** is a formula or other device to help in remembering. In the name mnemonic the underlined letters of the mnemonic correspond to the first letter(s) of the cranial nerve.

Other mnemonics: On Occasion Our Trusty Truck Acts Funny; Very Good Vehicle AnyHow  
Oh, Oh, Oh, To Touch And Feel Very Good Velvet, AH!  
Only Old Oranges Taste Terrible And Feel Very Grainy Veiny And Hard  
Oh, Once One Takes The Anatomy Final, Very Good Vacation Ahead

In the function mnemonic the underlined letters correspond to the function of the cranial nerve, i.e., S = sensory only, M = motor only, and B = both sensory and motor. Motor functions here include somatic motor (skeletal muscle) and parasympathetic motor (cardiac muscle, smooth muscle, and glands).

Brainstem death can be determined by the absence of certain brainstem reflexes.

Normal Reflexes that are Absent in Brainstem Death	Nerves Involved	Location of Brainstem Nuclei
Pupillary reflex Pupils constrict in response to light	S: Optic (II) M: Oculomotor (III)	Midbrain Midbrain
Oculocephalic reflex Move head swiftly to one side; the eyes move in the opposite direction (doll's eyes)	S: Vestibulocochlear (VIII) M: Oculomotor (III) Abducens (VI)	Pons Pons Midbrain
Vestibulo-ocular reflex Put ice-cold water in the ear; eyes move toward opposite ear	S: Vestibulocochlear (VIII) M: Oculomotor (III) Abducens (VI)	Pons Pons Midbrain
Corneal reflex Touch cornea; blink	S: Trigeminal (V) M: Facial (VII)	Pons Pons
Grimace (pain) reflex Response to pain stimuli on supraorbital ridge or fingernail	S: Trigeminal (V) Spinal cord M: Facial (VII)	Pons Pons
Cough and gag reflexes Cough: stimulate trachea with endotracheal tube Gag: stimulate pharynx	S: Glossopharyngeal (IX) Vagus (X) M: Glossopharyngeal (IX) Vagus (X) Phrenic to diaphragm	Medulla oblongata Medulla oblongata Medulla oblongata Medulla oblongata Medulla oblongata Also cough and gag centers in medulla oblongata
Absence of spontaneous breathing	S: Glossopharyngeal (IX) Vagus (X) M: Phrenic to diaphragm	Medulla oblongata Medulla oblongata Medulla oblongata Also respiratory center in medulla oblongata

S = Sensory input

M = Motor output

Basic premises:

1. The brainstem has many nuclei. i.e., sensory cranial nuclei, motor cranial nuclei, and reticular formation nuclei.
2. The presence of a reflex indicates sensory input reaches nuclei (reflex centers), the nuclei are functioning properly, and output from the nuclei reaches effectors. The absence of a reflex is taken to indicate damage to the nuclei.
3. Several different reflexes are tested at each level of the brainstem. If all of them are nonresponsive, it indicates the brainstem is nonfunctional.

## Clinical Applications

1. What cranial nerve would be damaged in order to produce the following symptoms?
  - a. difficulty hearing
  - b. anosmia (loss of the sense of smell)
  - c. blindness
  
2. Wendy Frost went cross country skiing on a very cold day. Afterwards she was unable to close her right eye or raise her right eyebrow. Although she could move her jaw, she had difficulty chewing because food would drool out of her mouth. What nerve was affected? Explain the observed symptoms.
  
3. A patient was diagnosed as having tic douloureux. In this condition, a light touch to the upper lip, cheek or under the eye or chewing, produces a sudden sensation of severe pain in and around the area touched. Although the cause of tic douloureux is unknown, what nerve must be involved?
  
4. Skip Puck slid into some other players while playing hockey and was severely injured by a skate blade, producing a deep cut in the neck on the left side just lateral to the larynx. After the wound was sutured, the following observations were made: The tongue, when protruded, deviated to the left; the left shoulder was drooping; and Skip could not turn his head to the right side. Name the nerves that were damaged and explain why this damage produced the observed symptoms.



## Cranial Nerve Functions

1. Name the three cranial nerves that have only sensory function. Give the function for each nerve.

Olfactory (I) - sense of smell

Optic (II) - sense of vision

Vestibulocochlear (VIII) - senses of hearing and balance

2. Name the cranial nerves responsible for the following sensory functions:

General sensory for the face, nasal cavity, and oral cavity: Trigeminal (V)

Sense of taste from anterior two-thirds of the tongue: Facial (VII)

Sense of taste from posterior one-third of the tongue: Glossopharyngeal (IX)

3. Name the three cranial nerves that supply the extrinsic eye muscles.

Oculomotor (III), Trochlear (IV), and Abducens (VI)

4. Name the cranial nerve responsible for the following motor functions:

Muscles of mastication: Trigeminal (V)

Muscles of facial expression: Facial (VII)

Tongue muscles: Hypoglossal (XII)

Laryngeal muscles of voice production: Vagus (X)

Trapezius and sternocleidomastoid muscles: Accessory (XI)

5. Name the three cranial nerves supplying the muscles involved with swallowing.

Glossopharyngeal (IX), Vagus (X), Accessory (XI)

6. Name the four cranial nerves that have parasympathetic functions. List the functions for each nerve.

Oculomotor (III) - intrinsic eye muscles

Facial (VII) - salivary glands (submandibular and sublingual) and lacrimal glands

Glossopharyngeal (IX) - salivary glands (parotid)

Vagus (X) - thoracic and abdominal organs