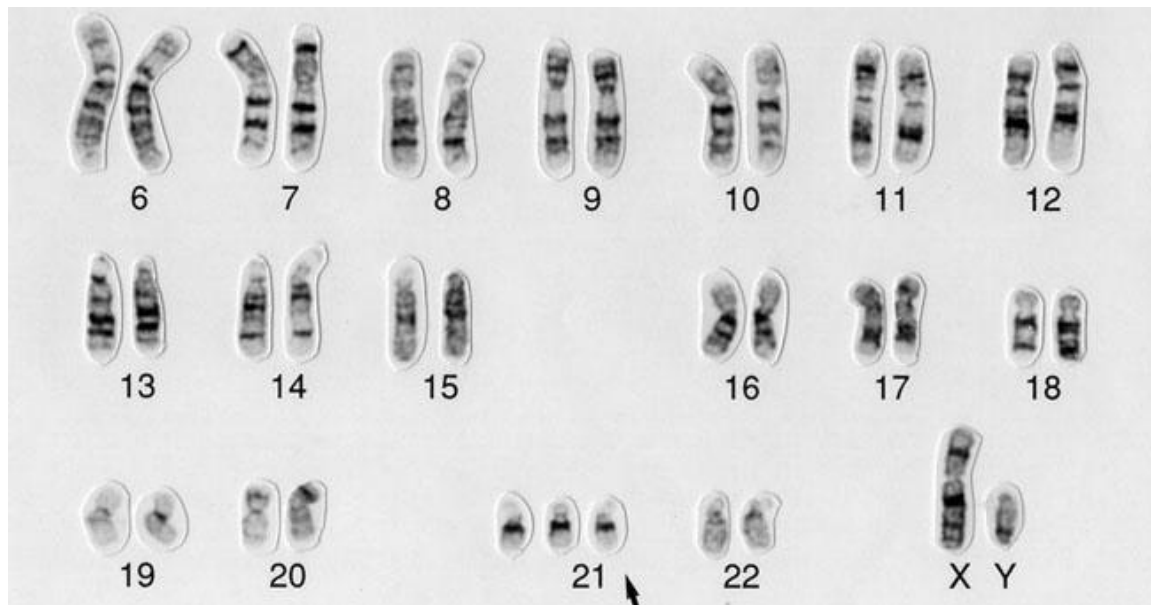


Patient Age: 3**Sex:** Male Female**KARYOTYPE:****ANATOMICAL TRAITS:**

3 year-old male with flat facial profile, broad forehead, and short neck. Outer sides of the eyes are slanted upward. Brushfield's spots in both eyes. Strabismus. Small mouth with slightly protruding tongue. Short stature. Slightly obese. Short arms and legs. Hands short and broad, with a single palmar crease. Short fingers. Hypotonia

PHYSIOLOGICAL TRAITS:

Congenital heart disease (ventricular septal defect, VSD, and atrioventricular canal). Frequent ear infections.

BEHAVIORAL/COGNITIVE TRAITS:

Significant cognitive impairment. Unable to articulate intelligible words. Walks with difficulty.